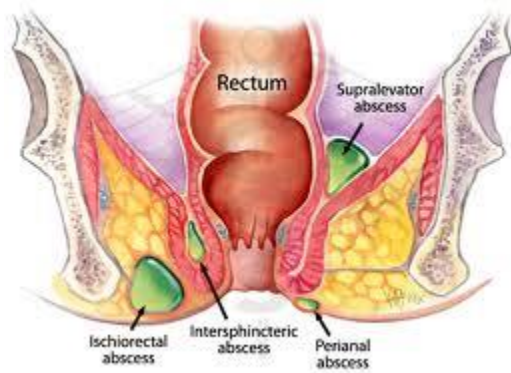


## Perianal Abscess and Fistula-in-ano

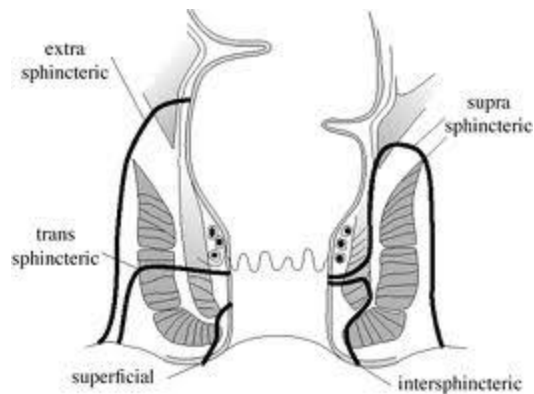
### *Background*

Anorectal abscesses are some of the more common anorectal conditions encountered, and they are potentially debilitating conditions. The current theory as to their cause is that they most often originate from a **cryptoglandular infection** in the anal canal. The anal glands are normal anatomic structures, are approximately 4 to 6 in number, and are usually located in the space between the internal and external anal sphincter. Their function is to lubricate the anal canal, their product is delivered through ducts which open into the anal canal at the base of the crypts in the dentate line. While the pathogenesis is the same in the majority of patients, these abscesses can be classified into **perianal, ischiorectal, intersphincteric and supralelevator** based on location. Other causes include Crohn's disease, trauma, foreign objects, radiation, and malignancy.



Patients may present with fever, pain, tenderness, erythema and/or a fluctuant mass. Alternatively, they may have a relatively normal external exam, but complain of deep-seated rectal pain. In these latter instances, one must have a high index of suspicion as to their presence or else they may go undiagnosed and escape proper treatment.

In approximately 30-50% of patients with anorectal abscess, a persistent tract, or fistula-in-ano, develops, extending from the anal canal to the perianal skin. Unfortunately, there is no definitive way to predict who will develop one, or how to prevent one. Studies have shown that if culture of the pus obtained from an abscess grows enteric (gram negative) organisms, as opposed to skin flora, the likelihood of there being an underlying fistula is increased. Patients often report persistent purulent drainage or cyclical perianal swelling and tenderness followed by spontaneous discharge. Other clues as to their presence include recurrent abscesses which develop at the same location and a non healing wound after incision and drainage of an abscess. Fistulas are categorized based on their anatomical course relative to the sphincter complex: **intersphincteric, transsphincteric, suprasphincteric and extrasphincteric**.



Fistulas can also be classified as “simple” or “complex,” with simple fistulas including low transsphincteric and intersphincteric fistulas that cross <30% of the external sphincter. Complex fistulas include high transsphincteric fistulas with or without a high blind tract, suprasphincteric and extrasphincteric fistulas, horseshoe fistulas, and those associated with inflammatory bowel disease, radiation, malignancy, preexisting incontinence or chronic diarrhea. Given the attenuated nature of the anterior sphincter complex in women, fistulas in this location deserve special consideration and may be considered complex as well.

### *Diagnosis*

The diagnosis of anorectal abscess is usually made based on history and physical examination. It is important to distinguish anorectal abscess from other perianal suppurative processes such as hidradenitis suppurativa, infected skin furuncles and other infectious processes including herpes simplex virus, HIV, TB, syphilis and actinomyces. Features suggestive of Crohn’s disease, including large skin tags or multiple fistulas require a more detailed work-up. The fistulas associated with hidradenitis have an internal opening caudal to the dentate line whereas cryptoglandular fistulas have their internal opening at the dentate line. The internal openings of an extrasphincteric fistula is cephalad to the dentate line.

On examination, a tender, fluctuant mass is usually present with perianal and ischioanal abscesses. Patients with intersphincteric or supralelevator abscess may have no external findings, with only pelvic or rectal tenderness with fluctuance on digital rectal exam. Careful inspection and palpation may detect the presence of other anorectal pathology or an external opening or tract suggestive of fistula. Anoscopy may be performed to attempt to visualize the internal opening of a fistula or other mucosal abnormalities. Laboratory evaluation is generally not necessary with the exception of patients with systemic symptoms such as fever, serious underlying medical problems, or an unclear diagnosis.

Studies such as fistulography, endoanal ultrasound, CT scan and MRI may be considered in patients to help define the anatomy of an anorectal abscess and help guide treatment in more complex cases. The vast majority of abscess and fistulas do not require imaging.

### *Treatment of Abscess*

Patients with acute anorectal abscess should be treated with incision and drainage. In general, the incision should be kept as close as possible to the anal verge to minimize the length of a potential fistula, while still providing adequate drainage. With an adequately sized elliptical incision, postoperative wound

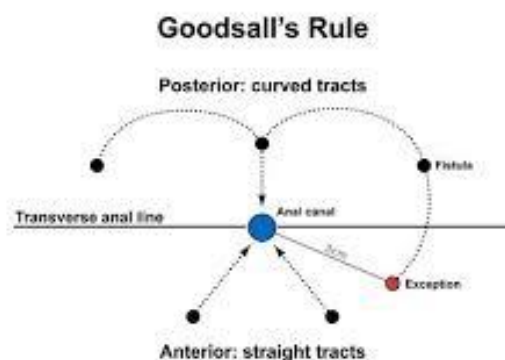
packing is usually not necessary. Incision and drainage can be carried out in the clinic or emergency room, however, if the patient is febrile, in extreme pain, or has a leukocytosis, incision and drainage may need to be performed in the operating room.

After simple incision and drainage, the overall recurrence rate ranges from 3% to 44%, depending on abscess location and length of follow-up. Additional factors associated with recurrence and the need for early repeat drainage include incomplete initial drainage, failure to break up loculations within the abscess, missed abscess and undiagnosed fistula. Horseshoe abscesses have been associated with especially high rates of persistence and recurrence ranging between 18% and 50%, and often require multiple operations before definitive healing.

Antibiotics have a limited role in the treatment of an uncomplicated anorectal abscess. In general, addition of antibiotics does not improve healing time or reduce recurrences and is therefore not indicated. However, antibiotics may be considered in patients with significant cellulitis, underlying immunosuppression, or concomitant systemic illness. Wound culture is rarely beneficial, although it may be considered in cases of recurrent infection or non-healing wounds. Patients that are immunosuppressed may also benefit from wound culture and targeted antibiotic treatment.

#### *Treatment of Fistula-in-Ano*

The goal of treatment of fistula-in-ano is to obliterate the internal fistulous opening and any associated epithelialized tracts with minimal sphincter division. Thus, **it is imperative to identify the internal opening** and the course of all tracts relative to the sphincter muscles. Goodsall's rule attempts to predict the location of the internal opening in relation to its external opening. External openings posterior to a transverse line through the anal verge will open into the anal canal in the midline. Conversely, anterior placed openings will run in a radial direction, analogous to "spokes on a wheel." Exceptions to Goodsall's rule are those instances when there are multiple fistulas, the external opening is more than 3 cm from the anus, and when the patient has Crohn's disease.



In addition to direct visualization and palpation, the surgeon must be familiar with adjunctive intraoperative measures, including hydrogen peroxide/methylene blue injection of the external opening, to assist in the identification of tract origin.

Because no single technique is appropriate for the treatment of all anal fistulas, treatment must be directed by the etiology and anatomy of the fistula, degree of symptoms, patient comorbidities and the surgeon's experience.

### *Fistulotomy*

Simple anal fistulas may be treated by fistulotomy with success rates of 92% to 97%. There is no universal answer to the question of how much muscle can safely be divided. The greatest concern is for post-operative incontinence with fistulotomy. Risk factors include preoperative incontinence, recurrent disease, female sex, complex fistulas and prior fistula surgery. The addition of marsupialization may improve the rate of wound healing.

### *Fibrin Glue*

Anal fistulas may be treated with debridement and fibrin glue injection. This treatment has a number of advantages, including its ease of use, repeatability, and avoidance of sphincter division. However, this must be weighed against the high failure rate. Success rates for treatment of simple fistulas are between 40% and 78%. Fibrin glue has relatively low success rates in complex disease; overall healing rates range from 10% to 67%. Given the low morbidity associated with the procedure, it may be considered for initial therapy.

### *Fistula Plug*

The bioprosthetic anal fistula plug is used to close the primary internal anal opening and serves as a matrix for the obliteration of the fistula tract. Majority of studies report success rates <50%. Again, the low morbidity, repeatability, and lack of other options warrant consideration of this treatment in patients with complex fistulas.

### *Endoanal Advancement Flap*

Endoanal advancement flap is another sphincter-sparing technique that consists of curettage of the tract, and mobilization of a segment of proximal healthy anorectal mucosa, submucosa and muscle to cover the site of the sutured internal opening. In general, failure rates range from 13% to 56%. Factors associated with failed repair include radiation, underlying Crohn's disease, active proctitis, rectovaginal fistula, malignancy, and number of prior attempted repairs.

### *Cutting Seton and Non-cutting Seton*

A cutting seton may be used to treat a complex anal fistula. The seton is passed through the fistula tract to convert an inflammatory process to a foreign body reaction causing perisphincteric fibrosis. Progressive tightening will produce a gradual fistulotomy effect with scarring of the tract, over the course of several weeks. Alternatively, a loose seton may be placed to promote drainage and avoidance of recurrent perianal sepsis, and may be left in place long-term or removed with ultimate cure planned. There remains a lack of high-quality data with regard to setons. The non-cutting seton is attractive for patients with Crohn's disease since they reduce the likelihood of future anorectal sepsis, need for surgery, and sphincter injury while allowing time for the underlying disease to be treated medically to the fullest extent possible. When the underlying Crohn's has been put into remission, the setons can be eventually removed with the

hope that the fistulas may then heal without further surgery. With this approach, sustained healing of anal fistulas is approximately 30%.

*Ligation of Intersphincteric Fistula Tract (LIFT)*

A relatively new technique called the LIFT procedure involves ligation and division of the fistula tract in the intersphincteric space. The procedure typically involves placement of a seton for 8 or more weeks to allow fibrosis of the tract. Using an intersphincteric approach the tract can be identified, ligated, and divided without violating the muscle. Theoretically, continence will be preserved. Although there is limited data, reported success rates range from 57% to 94%. If the LIFT procedure fails, the patient is usually left with a shorter, more superficial tract that can be treated with simple fistulotomy.

Adapted from The Practice Parameters from Diseases of the Colon & Rectum Volume 54:12, The ASRCS 2011